

CDw75 Ab-1 (Clone LN1)

Mouse Monoclonal Antibody

Cat. #MS-130-P0, -P1, or -P (0.1ml, 0.5ml, or 1.0ml at 200µg/ml) (Purified Ab with BSA and Azide)**Cat. #MS-130-P1ABX or -PABX (0.1ml or 0.2ml at 1.0mg/ml)** (Purified Ab without BSA and Azide)**Cat. #MS-130-R7 (7.0ml)** (Ready-to-Use for Immunohistochemistry)**Cat. #MS-130-PCS (5 Slides)** (Positive Control for Histology)

Please note this data sheet has been changed effective December 6, 2011

Description: CDw75 is a neuraminidase-sensitive sialoprotein, present on cell membrane and cytoplasm of germinal center B-cells and derived lymphomas. LN1 reacts with RBC precursors of bone marrow, ductal and ciliated epithelial cells of kidney, breast, prostate, pancreas, lung, and with glioblastomas, astrocytomas, and Reed Sternberg cells in lymphocyte predominant Hodgkin's disease. LN1 is shown to be a reliable antibody for ascribing a B-cell phenotype in known lymphoid tissues.

Mol. Wt. of Antigen: 53 and 87kDa**Epitope:** Not determined**Species Reactivity:** Human. Does not react with rat. Others-not known.**Clone Designation:** LN1 (Workshop IV)**Ig Isotype / Light Chain:** IgM / κ**Immunogen:** Nuclei from pokeweed mitogen-stimulated peripheral blood lymphocytes.**Applications and Suggested Dilutions:**

- Flow Cytometry
- Immunofluorescence
- Immunohistology (Formalin/paraffin)
(Ab at 1:25 – 1:50 for 20 - 30 min at RT)
- * [Staining of formalin-fixed tissues REQUIRES boiling tissue sections in 10mM citrate buffer, pH 6.0, (Lab Vision Cat. #AP-9003), for 10-20 min followed by cooling at RT for 20 min.]

The optimal dilution for a specific application should be determined by the investigator.

Positive Control: Lymph node or tonsil.**Cellular Localization:** Cell membrane**Storage and Stability:**

Ab with sodium azide is stable for 24 months when stored at 2-8°C. Antibody WITHOUT sodium azide is stable for 36 months when stored at below 0°C.

Supplied As:

200µg/ml antibody purified from the ascites fluid by ammonium sulfate precipitation and prepared in 10mM PBS, pH 7.4, with 0.2% BSA and 0.09% sodium azide. Also available without BSA and azide at 1mg/ml, or Prediluted antibody which is ready-to-use for staining of formalin-fixed, paraffin-embedded tissues.

Key References:

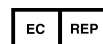
1. Mason DY; et al American Journal of Surgical Pathology, 1994, 18:526-30.
2. Akasu R; et al. American Journal of Dermatopathology, 1993, 15(3):217-23.

Limitations and Warranty:

Our products are intended FOR RESEARCH USE ONLY and are not approved for clinical diagnosis, drug use or therapeutic procedures. No products are to be construed as a recommendation for use in violation of any patents. We make no representations, warranties or assurances as to the accuracy or completeness of information provided on our data sheets and website. Our warranty is limited to the actual price paid for the product. Lab Vision is not liable for any property damage, personal injury, time or effort or economic loss caused by our products.

Material Safety Data:

This product is not licensed or approved for administration to humans or to animals other than the experimental animals. Standard Laboratory Practices should be followed when handling this material. The chemical, physical, and toxicological properties of this material have not been thoroughly investigated. Appropriate measures should be taken to avoid skin and eye contact, inhalation, and ingestion. The material contains 0.09% sodium azide as a preservative. Although the quantity of azide is very small, appropriate care should be taken when handling this material as indicated above. The National Institute of Occupational Safety and Health has issued a bulletin citing the potential explosion hazard due to the reaction of sodium azide with copper, lead, brass, or solder in the plumbing systems. Sodium azide forms hydrazoic acid in acidic conditions and should be discarded in a large volume of running water to avoid deposits forming in metal drainage pipes.

For Research Use Only

CDw75 Ab-1 (Clone LN1)

Mouse Monoclonal Antibody

Cat. #MS-130-P0, -P1, or -P (0.1ml, 0.5ml, or 1.0ml at 200µg/ml) (Purified Ab with BSA and Azide)

Cat. #MS-130-P1ABX or -PABX (0.1ml or 0.2ml at 1.0mg/ml) (Purified Ab without BSA and Azide)

Cat. #MS-130-R7 (7.0ml) (Ready-to-Use for Immunohistochemistry)

Cat. #MS-130-PCS (5 Slides) (Positive Control for Histology)

Please note this data sheet has been changed effective December 6, 2011

Additional Key References:

1. Becker JL; Prewett TL; Spaulding GF; Goodwin TJ. Three-dimensional growth and differentiation of ovarian tumor cell line in high aspect rotating-wall vessel: morphologic and embryologic considerations. *Journal of Cellular Biochemistry*, 1993, 51(3):283-9.
2. Enblad G; Sundstrom C; Glimelius B. Immunohistochemical characteristics of Hodgkin and Reed-Sternberg cells in relation to age and clinical outcome. *Histopathology*, 1993, 22(6):535-41.
3. Kanavaros P; Mikol J; Nemeth J; Galian A; Vaunaize J; Morinet F; Thurel C. Primary T-cell malignant lymphoma of the central nervous system: Histological, immunohistochemical and ultrastructural study of a case. *Path Res Pract*, 1993, 189: 93-8.
4. Perkins SL; Kjeldsberg CR. Immunophenotyping of lymphomas and leukemias in paraffin-embedded tissues. *Hematopathology*, 1993, 99: 362-73.
5. Sepp N; Radaszkiewicz T; Meijer CJ; Smolle J; Seewann H; Fritsch P; Kerl H. Specific skin manifestations in acute leukemia with monocytic differentiation. A morphologic and immunohistochemical study of 11 cases. *Cancer*, 1993, 71(1):124-32.
6. Shin SS; Ben-Ezra J; Burke JS; Sheibani K; Rappaport H. Reed-Sternberg-like cells in low-grade lymphomas are transformed neoplastic cells of B-cell lineage. *Am J of Clinical Pathology*, 1993, 99:658-62.
7. Tallini G; West B; Buckley PJ. Diagnosis of gastrointestinal T-cell lymphomas in routinely processed tissues. *J Clin Gastroenterol*, 1993, 17: 57-66.
8. Akasu R; Kahn HJ; From L. Lymphocyte markers on formalin-fixed tissue in Jessner's lymphocytic infiltrate and lupus erythematosus. *Journal of Cutaneous Pathology*, 1992, 19:59-65.
9. Baddoura FK; Hanson C; Chan WC. Plasmacytoid monocyte proliferation associated with myeloproliferative disorders. *Cancer*, 1992, 69(6):1457-67.
10. Bast BJEG; Zhou LJ; Freeman GJ; Colley KJ; Ernst TJ; Munro JM Tedder TF. The HB-6 CDw75 and CD76 differentiation antigens are unique cell-surface carbohydrate determinants generated by the β -Galactoside α 2,6-sialyltransferase. *J Cell Bio*, 1992, 116: 423-35.
11. Carbone; Pinto A; Gloghini A; Volpe R; Zagonel V. B-zone small lymphocytic lymphoma: A morphologic, immunophenotypic, and clonal study with comparison to "well differentiated" lymphocytic disorders. *Hum Pathol*, 1992, 23: 438-48.
12. Facchetti F; Agostini C; Chilosi M; Mombello A; Grigolato P; Van den Oord JJ. Suppurative granulomatous lymphadenitis. Immunohistochemical evidence for a B-cell-associated granuloma. *American Journal of Surgical Pathology*, 1992, 16(10):955-61.
13. Feldges A; Gerhard L; Reinhardt V; Budach V. Primary cerebral anaplastic T-cell-lymphoma (type Ki-1): review and case report. *Clinical Neuropathology*, 1992, 11(2):55-9.
14. Fukuda T; Ohnishi Y; Emura I; Tachikawa S. Microcytic variant of thymoma: histological and immunohistochemical findings in two cases. *Virchows Archiv. a, Pathological Anatomy and Histopathology*, 1992, 420(2):185-9.
15. Lauritzen AF; Pluzek KJ; Kristensen LE; Nielsen HW. Detection of immunoglobulin light chain mRNA in nodular sclerosing Hodgkin's disease by in situ hybridization with biotinylated oligonucleotide probes compared with immunohistochemical staining with poly- and monoclonal antibodies. *Histopathology*, 1992, 21(4):353-8.
16. Lavergne A; Kanavaros P; Galian A. Primary B-cell gastric lymphomas of mucosa-associated lymphoid tissue. Histological and immunohistochemical study of ten cases on surgical specimens. *Histology and Histopathology*, 1992, 7(1):129-36.
17. Lee J; Sun NC; Salahi W; Chen H; Yang MH. A clinicopathologic study on the diffuse malignant lymphoma--a morphologic and immunophenotypic analysis in 62 patients at Harbor-UCLA Medical Center. *Journal of Korean Medical Science*, 1992, 7(3):204-13.
18. Lynch JW Jr; Linoilla I; Sausville EA; Steinberg SM; Ghosh BC; Nguyen DT; Schechter GP; Fischmann AB; Ihde DC; Stocker JL; et al. Prognostic implications of evaluation for lymph node involvement by T-cell antigen receptor gene rearrangement in mycosis fungoides. *Blood*, 1992, 79(12):3293-9.
19. O'Keane JC; Stahl D; Sheahan K; Burke B; Gottlieb LS; O'Brien MJ. Analysis of epithelial and lymphoid phenotypic markers in relation to growth pattern of colorectal adenomas. *Human Pathology*, 1992, 23(9):1038-43.
20. Shin SS; Sheibani K; Kezirian J; Nademanee A; Forman SJ; Lee SK; Winberg CD. Immunoarchitecture of normal human bone marrow: a



CDw75 Ab-1 (Clone LN1)

Mouse Monoclonal Antibody

Cat. #MS-130-P0, -P1, or -P (0.1ml, 0.5ml, or 1.0ml at 200µg/ml) (Purified Ab with BSA and Azide)

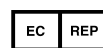Cat. #MS-130-P1ABX or -PABX (0.1ml or 0.2ml at 1.0mg/ml) (Purified Ab without BSA and Azide)

Cat. #MS-130-R7 (7.0ml) (Ready-to-Use for Immunohistochemistry)

Cat. #MS-130-PCS (5 Slides) (Positive Control for Histology)

Please note this data sheet has been changed effective December 6, 2011

- study of frozen and fixed tissue sections. Human Pathology, 1992, 23(6):686-94.
21. Stroup R; Sheibani K. Antigenic phenotypes of hairy cell leukemia and monocytoid B-cell lymphoma: an immunohistochemical evaluation of 66 cases. Human Pathology, 1992, 23(2):172-7.
 22. Beljaards RC; Meijer CJ; Scheffer E; van der Valk P; Willemze R. Differential diagnosis of cutaneous large cell lymphomas using monoclonal antibodies reactive in paraffin-embedded skin biopsy specimens. American Journal of Dermatopathology, 1991, 13(4):342-9.
 23. Campo E; Cardesa A; Alos L; Palacin A; Cobarro J; Traserra J; Montserrat E. Non-Hodgkin's lymphomas of nasal cavity and paranasal sinuses: An immunohistochemical study. Am J Clin Pathol, 1991, 96: 184-90.
 24. Gaulier A; Sabatier P; Prevot S; Fournier JG. Do measles early giant cells result from fusion of non-infected cells? An immunohistochemical and in situ hybridization study in a case of morbillous appendicitis. Virchows Archiv. a, Pathological Anatomy and Histopathology, 1991, 419(3):245-9.
 25. Lauritzen AF; Ralfkiaer E. Use of monoclonal antibodies for the typing of malignant lymphomas in routinely processed biopsy samples. Apmis, 1991, 99(7):631-9.
 26. Mielke B; Möller P. Histomorphic and immunophenotypic spectrum of primary gastrointestinal B-cell lymphomas. Int J Cancer, 1991, 47: 334-43.
 27. Pich A; Gastaldi M; Tragni G; Navone R. Lymphocyte subsets in bone marrow lymphoid nodules and malignant lymphoma nodular involvement. European J of Basic and Applied Histochemistry, 1991, 35:81-9.
 28. Pileri S, Falini B, Sabatini E, Bigerna B, Gherlinzonii F, and Tazzari PL. Immunohistochemistry of malignant lymphomas. Advantages and limitations of the new monoclonal antibodies working in paraffin sections. Haematologica, 1991, 76: 226-34.
 29. Santucci M; Pimpinelli N; Arganini L. Primary cutaneous B-cell lymphoma: A unique type of low-grade lymphoma, Clinicopathologic and immunologic study of 83 cases. Cancer, 1991, 67: 2311-2326.
 30. Schmid C; Pan L; Diss T; Isaacson PG. Expression of B-cell antigens by Hodgkin's and Reed-Sterberg cells. Am J Pathol, 1991, 139: 701-7.
 31. Taubenberger JK; Cole DE; Raffeld M; Poplack DG; Jaffe ES; Medeiros LJ. Immunophenotypic analysis of acute lymphoblastic leukemia using routinely processed bone marrow specimens. Archives of Pathology and Laboratory Medicine, 1991, 115(4):338-42.
 32. Casey TT; Cousar JB; Mangum M; Williams ME; Lee JT; Greer JP; Collins RD. Monomorphic lymphomas arising in patients with Hodgkin's disease. Correlation of morphologic, immunophenotypic, and molecular genetic findings in 12 cases. American Journal of Pathology, 1990, 136(1):81-94.
 33. Cerio R; Oliver GF; Jones EW; Winkelmann RK. The heterogeneity of Jessner's lymphocytic infiltration of the skin. Immunohistochemical studies suggesting one form of perivascular lymphocytoma. Journal of the American Academy of Dermatology, 1990, 23(1):63-7.
 34. Cerroni L; Smolle J; Soyer P; Aparicio AM; Kerl H. Immunophenotyping of cutaneous lymphoid infiltrates in frozen and paraffin-embedded tissue sections: A comparative study. J Am Acad Dermatol, 1990, 22: 405-13.
 35. Chilosi M; Mombello A; Menestrina F; Gilioli E; Manfrin E; Pizzolo G; Fiore-Donati L. Immunohistochemical differentiation of follicular lymphoma from florid reactive follicular hyperplasia with monoclonal antibodies reactive on paraffin sections. Cancer, 1990, 65(7):1562-9.
 36. Chittal SM; Alard C; Rossi J-F; Al Saati T; Le Tourneau A; Diebold J; Delsol G. Further phenotypic evidence that nodular, lymphocyte-predominant Hodgkin's disease is a large B-cell lymphoma in evolution. Am J Surg Pathol, 1990, 14: 1024-35.
 37. Davey FR; Elghetany MT; Kurec AS. Immunophenotyping of hematologic neoplasms in paraffin-embedded tissue sections. American J of Clinical Pathology, 1990, 93(4 Suppl 1):S17-26.
 38. Duggan MJ; Weisenburger DD; Ye YL; Bast MA; Pierson JL; Linder J; Armitage JO. Mantle zone lymphoma. A clinicopathologic study of 22 cases. Cancer, 1990, 66(3):522-9.
 39. Faure P, Chittal S, Gorguet P, Viraben R, Mazerolles C, and Delsol G. Immunohistochemical profile of cutaneous B-cell lymphoma on cryostat and paraffin sections. Am J Derm 12: 122-133, 1990.
 40. Hassan IB; Hagberg H; Sundstrom C. Immunophenotype of hairy-cell leukemia. European Journal of Haematology, 1990, 45(3):172-6.
 41. Kahn HJ; Thorner PS. Monoclonal antibody MT1: a marker for Langerhans cell histiocytosis. Pediatric Pathology, 1990, 10(3):375-84.



CDw75 Ab-1 (Clone LN1)

Mouse Monoclonal Antibody

Cat. #MS-130-P0, -P1, or -P (0.1ml, 0.5ml, or 1.0ml at 200µg/ml) (Purified Ab with BSA and Azide)

Cat. #MS-130-P1ABX or -PABX (0.1ml or 0.2ml at 1.0mg/ml) (Purified Ab without BSA and Azide)

Cat. #MS-130-R7 (7.0ml) (Ready-to-Use for Immunohistochemistry)

Cat. #MS-130-PCS (5 Slides) (Positive Control for Histology)

Please note this data sheet has been changed effective December 6, 2011

42. Kanavaros P; Mikol J; Nemeth J; Galian A; Dupont B; Thiebaut JB; Thurel C. Stereotactic biopsy diagnosis of primary non-Hodgkin's lymphoma of the central nervous system. A histological and immunohistochemical study. *Pathology, Research and Practice*, 1990, 186(4):459-66.
43. Kornstein MJ; Kay S. B cells in thymomas. *Modern Pathology*, 1990, 3(1):61-3.
44. Mechtersheimer G; Krüger KH; Born IA; Möller P. Antigen profile of mammary fibroadenoma and cytosarcoma phyllodes: A study using antibodies to estrogen- and progesterone receptors and to a panel of cell surface molecules. *Path Res Pract*, 1990, 186:427-38.
45. Timens W; Kamps WA; Rozeboom-Uiterwijk T; Poppema S. Haemopoiesis in human fetal and embryonic liver. Immunohistochemical determination in B5-fixed paraffin-embedded tissues. *Virchows Archiv. a, Pathological Anatomy and Histopathology*, 1990, 416(5):429-36.
46. Valente G; Ferrara P; Stramignoni A. Lymphocyte populations of non-sclerodular Hodgkin's disease subtypes in different stages of lymphocyte depletion. An immunophenotypic and quantitative study. *Virchows Archiv. B. Cell Pathology*, 1990, 58(4):289-94.
47. Wick MR; Mills SE; Swanson PE. Expression of "myelomonocytic" antigens in mesotheliomas and adenocarcinomas involving the serosal surfaces. *American Journal of Clinical Pathology*, 1990, 94(1):18-26.
48. Yoshino T; Hoshida Y; Murakami I; Takahashi K; Akagi T. Comparison of monoclonal antibodies reactive with lymphocyte subsets in routinely fixed paraffin-embedded material: flow cytometric analyses, immunoperoxidase staining and influence of fixatives. *Acta Medica Okayama*, 1990, 44(5):243-50.
49. Carbone A; Gloghini A; Pinto A; Attadia V; Zagonel V; Volpe R. Monocytoid B-cell lymphoma with bone marrow and peripheral blood involvement at presentation [see comments]. *American Journal of Clinical Pathology*, 1989, 92(2):228-36.
50. Facchetti F; de Wolf-Peeters C; van den Oord JJ; de Vos R; Desmet VJ. Plasmacytoid monocytes (so-called plasmacytoid T-cells) in Kikuchi's lymphadenitis. An immunohistologic study. *American Journal of Clinical Pathology*, 1989, 92(1):42-50.
51. Katzin WE; Linden MD; Fishleder AJ; Tubbs RR. Immunophenotypic and genotypic characterization of diffuse mixed non-Hodgkin's lymphomas. *American Journal of Pathology*, 1989, 135(4):615-21.
52. Kubic VL; Brunning RD. Immunohistochemical evaluation of neoplasms in bone marrow biopsies using monoclonal antibodies reactive in paraffin-embedded tissue. *Modern Pathology*, 1989, 2(6):618-29.
53. Leong AS; Gilham PN. The effects of progressive formaldehyde fixation on the preservation of tissue antigens. *Pathology*, 1989, 21(4):266-8.
54. Maes M; Bosmans E; Suy E; Minner B; Raus J. Immune cell parameters in severely depressed patients: negative findings. *Journal of Affective Disorders*, 1989, 17(2):121-8.
55. Nakhleh RE; Manivel JC; Hurd D; Sung JH. Central nervous system lymphomas. Immunohistochemical and clinicopathologic study of 26 autopsy cases. *Archives of Pathology and Laboratory Medicine*, 1989, 113(9):1050-6.
56. Norton AJ; Isaacson PG. Lymphoma phenotyping in formalin-fixed and paraffin wax-embedded tissues. I. Range of antibodies and staining patterns. *Histopathology*, 1989, 14: 437-46.
57. Wick MR; Mills SE; Dehner LP; Bollinger DJ; Fechner RE. Serous papillary carcinomas arising from the peritoneum and ovaries. A clinicopathologic and immunohistochemical comparison. *International Journal of Gynecological Pathology*, 1989, 8(3):179-88.
58. Zbieranowski I; Kahn HJ; Hanna W. Epithelial proliferation in thymic hyperplasia. An immunohistochemical study and correlation with the developing fetal thymus. *Archives of Pathology and Laboratory Medicine*, 1989, 113(4):385-9.
59. Andrade RE; Wick MR; Frizzera G; Gajl-Peczalska KJ. Immunophenotyping of hematopoietic malignancies in paraffin sections. *Hum Pathol*, 1988, 19: 394-402.
60. Coles FB; Cartun RW; Pastuszak WT. Hodgkin's disease, lymphocyte-predominant type: immunoreactivity with B-cell antibodies. *Modern Pathology*, 1988, 1(4):274-8.
61. Davey FR; Olson S; Kurec AS; Eastman-Abaya R; Gottlieb AJ; Mason DY. The immunophenotyping of extramedullary myeloid cell tumors in paraffin-embedded tissue sections. *American Journal of Surgical Pathology*, 1988, 12(9):699-707.
62. Facchetti F; De Wolf-Peeters C; van den Oord JJ; De vos R; Desmet VJ. Plasmacytoid T cells: a cell population normally present in the reactive lymph



CDw75 Ab-1 (Clone LN1)

Mouse Monoclonal Antibody

Cat. #MS-130-P0, -P1, or -P (0.1ml, 0.5ml, or 1.0ml at 200µg/ml) (Purified Ab with BSA and Azide)

Cat. #MS-130-P1ABX or -PABX (0.1ml or 0.2ml at 1.0mg/ml) (Purified Ab without BSA and Azide)

Cat. #MS-130-R7 (7.0ml) (Ready-to-Use for Immunohistochemistry)

Cat. #MS-130-PCS (5 Slides) (Positive Control for Histology)

Please note this data sheet has been changed effective December 6, 2011

- node. An immunohistochemical and electronmicroscopic study. *Human Pathology*, 1988, 19:1085-92.
63. Hall PA; d'Ardenne AJ; Stansfeld AG. Paraffin section immunohistochemistry. I. Non-Hodgkin's lymphoma. *Histopathology*, 1988, 13(2):149-60.
 64. Linder J; Ye Y; Armitage JO; Weisenburger DD. Monoclonal antibodies marking B-cell non-Hodgkin's lymphoma in paraffin-embedded tissue. *Modern Pathology*, 1988, 1:29-34.
 65. Norton AJ; Ramsay AD; Isaacson PG. Antigen preservation in infarcted lymphoid tissue. A novel approach to the infarcted lymph node using monoclonal antibodies effective in routinely processed tissues. *American Journal of Surgical Pathology*, 1988, 12(10):759-67.
 66. Timens W; Boes A; Rozeboom-Uiterwijk T; Poppema S. Immuno-architecture of human fetal lymphoid tissues. *Virchows Archiv. a, Pathological Anatomy and Histopathology*, 1988, 413(6):563-71.
 67. Wieczorek R; Buck D; Bindl J; Knowles DM. Monoclonal antibody Leu-22 (L60) permits the demonstration of some neoplastic T cells in routinely fixed and paraffin-embedded tissue sections. *Human Pathology*, 1988, 19(12):1434-43.
 68. Linder J; Ye Y; Harrington DS; Armitage JO; Weisenburger DD. Monoclonal antibodies marking T lymphocytes in paraffin-embedded tissue. *Am J Pathol*, 1987, 127: 1-8.
 69. Ng CS; Chan JK; Lo ST; Lo DS. Critical assessment of four monoclonal antibodies reactive with B-cells in formalin-fixed paraffin-embedded tissues. *Histopathology*, 1987, 11:1243-58.
 70. Norton AJ; Isaacson PG. Detailed phenotypic analysis of B-cell lymphoma using a panel of antibodies reactive in routinely fixed wax-embedded tissue. *American Journal of Pathology*, 1987, 128(2):225-40.
 71. Norton AJ; Isaacson PG. The diagnosis of malignant lymphoma using monoclonal antibodies reactive in routinely fixed wax embedded tissue. *J of Pathol*, 1987, 151: 183-4.
 72. Poppema S, Hollema H, Visser L, and Vos H. Monoclonal antibodies (MT1, MT2, MB1, MB2, MB3) reactive with leukocyte subsets in paraffin-embedded tissue sections. *Am J Pathol*, 1987, 127: 418-29.
 73. Sheibani K; Battifora H; Winberg CD; Burke JS; Ben-Ezra J; Ellinger GM; Quigley NJ; Fernandez BB; Morrow D; Rappaport H. Further evidence that "malignant angioendotheliomatosis" is an angiotropic large-cell lymphoma. *New England Journal of Medicine*, 1986, 314(15):943-8.
 74. Sherrod AE; Felder B; Levy N; Epstein A; Marder R; Lukes RJ; Taylor CR. Immunohistologic identification of phenotypic antigens associated with Hodgkin and Reed-sternberg cells: A paraffin section study. *Cancer*, 1986, 57: 2135-40.
 75. Okhon E; Felder B; Epstein A; Lukes RJ; Taylor CR. Monoclonal antibodies reactive with B-lymphocytes and histiocytes in paraffin sections. *Cancer*, 1985, 56: 95-104.
 76. Sausville EA; Worsham GF; Matthews MJ; Makuch RW; Fischmann AB; Schechter GP; Gazdar AF; Bunn PA Jr. Histologic assessment of lymph nodes in mycosis fungoides/Sezary syndrome (cutaneous T-cell lymphoma): clinical correlations and prognostic import of a new classification system. *Human Pathology*, 1985, 16(11):1098-109.
 77. Marder RJ, Varakojis D, Silver J, and Epstein AL. Immunohistochemical analysis of human lymphomas with monoclonal antibodies to B Cell and Ia antigens reactive in paraffin sections. *Lab Invest* 52: 497-504, 1985.
 78. Epstein AL, Marder RJ, Winter JN, and Fox RI. Two new monoclonal antibodies (LN-1, LN-2) reactive in B5 formalin-fixed, paraffin-embedded tissues with follicular center and mantle zone human B lymphocytes and derived tumors. *J of Immunology* 133: 1028-1036, 1984.

