

**CD45RO (T-Cell Marker) Ab-1 (Clone UCHL-1)**

Mouse Monoclonal Antibody

**Cat. #MS-112-P0, -P1, or -P (0.1ml, 0.5ml, or 1.0ml at 100µg/ml)** (Purified Ab with BSA and Azide)**Cat. #MS-112-P1ABX or -PABX (0.1ml or 0.2ml at 1.0mg/ml)** (Purified Ab without BSA and Azide)**Cat. #MS-112-R7 (7.0ml)** (Ready-to-Use for Immunohistochemistry)**Cat. #MS-112-RQ (12.0ml)** (Ready-to-use for Immunohistochemistry)**Cat. #MS-112-PCS (5 Slides)** (Positive Control for Histology)**Please note this data sheet has been changed effective December 6, 2011**

**Description:** CD45RO (an isoform of leukocyte common antigen) is expressed on most thymocytes, monocytes, macrophages and granulocytes. It is not expressed on normal B lymphocytes. Intrathymic T cell maturation progresses from CD45RA-/CD45RO+ to CD45RA+/CD45RO-; while peripheral T cell maturation progresses from CD45RA+/CD45RO- to CD45RA-/CD45RO+.

**Comments:** Ab-1 reacts with mature activated T-cells, most thymocytes, and a sub-population of resting T-cells within both CD4 and CD8 subsets. Shows no reactivity with normal B or natural killer cells, but reacts with granulocytes and monocytes. It rarely stains B cell lymphomas.

**Mol. Wt. of Antigen:** 180kDa**Epitope:** Not determined**Species Reactivity:** Human, Rhesus Monkey, and Chimpanzee. Does not react with rat. Others-not known.**Clone Designation:** UCHL-1 (Workshop IV)**Ig Isotype / Light Chain:** IgG<sub>2a</sub> / κ**Immunogen:**

Interleukin-2-dependent human T lymphocytes

**Applications and Suggested Dilutions:**

- Flow Cytometry
- Immunohistology (Formalin/paraffin)

Use Ab 1:200-400 for 20 min at RT using UltraVision LP Detection Systems

\* [No special pretreatment is required for immunohistochemistry of formalin/paraffin tissues]

Use Ab 1:800 for 20 min at RT using UltraVision Quanto Detection Systems

\* [Staining of formalin-fixed tissues requires boiling tissue sections in 10mM citrate buffer, pH 6.0 for 10-20 min followed by cooling at RT for 20 min.]

The optimal dilution for a specific application should be determined by the investigator.

**Positive Control:** Tonsil or lymph node**Cellular Localization:** Cell Membrane**Storage and Stability:**

Ab with sodium azide is stable for 24 months when stored at 2-8°C. Antibody WITHOUT sodium azide is stable for 36 months when stored at below 0°C.

**Supplied As:**

100µg/ml antibody purified from the ascites fluid by Protein A chromatography. Prepared in 10mM PBS, pH 7.4, with 0.2% BSA and 0.09% sodium azide. Also available without BSA and azide at 1mg/ml, or

Prediluted antibody which is ready-to-use for staining of formalin-fixed, paraffin-embedded tissues.

**Key References:**

1. Smith S H, et. al. (1986) Immunology, 58:63-70.
2. Leukocyte Typing III, p225-227.
3. Akbar A. N, et. al. (1988) J Immunol, 140:2171-2178.
4. Nature, 360:264-265.

**Limitations and Warranty:**

Our products are intended FOR RESEARCH USE ONLY and are not approved for clinical diagnosis, drug use or therapeutic procedures. No products are to be construed as a recommendation for use in violation of any patents. We make no representations, warranties or assurances as to the accuracy or completeness of information provided on our data sheets and website. Our warranty is limited to the actual price paid for the product. Lab Vision is not liable for any property damage, personal injury, time or effort or economic loss caused by our products.

**Material Safety Data:**

This product is not licensed or approved for administration to humans or to animals other than the experimental animals. Standard Laboratory Practices should be followed when handling this material. The chemical, physical, and toxicological properties of this material have not been thoroughly investigated. Appropriate measures should be taken to avoid skin and eye contact, inhalation, and ingestion. The material contains 0.1% sodium azide as a preservative. Although the quantity of azide is very small, appropriate care should be taken when handling this material as indicated above. The National Institute of Occupational Safety and Health has issued a bulletin citing the potential explosion hazard due to the reaction of sodium azide with copper, lead, brass, or solder in the plumbing systems. Sodium azide forms hydrazoic acid in acidic conditions and should be discarded in a large volume of running water to avoid deposits forming in metal drainage pipes.



**CD45RO (T-Cell Marker) Ab-1 (Clone UCHL-1)**

Mouse Monoclonal Antibody

**Cat. #MS-112-P0, -P1, or -P (0.1ml, 0.5ml, or 1.0ml at 100µg/ml)** (Purified Ab with BSA and Azide)**Cat. #MS-112-P1ABX or -PABX (0.1ml or 0.2ml at 1.0mg/ml)** (Purified Ab without BSA and Azide)**Cat. #MS-112-R7 (7.0ml)** (Ready-to-Use for Immunohistochemistry)**Cat. #MS-112-RQ (12.0ml)** (Ready-to-use for Immunohistochemistry)**Cat. #MS-112-PCS (5 Slides)** (Positive Control for Histology)**Please note this data sheet has been changed effective December 6, 2011****For Research Use Only****Additional Key References:**

5. Mori N; Yatabe Y; Oka K; Yokose T; Ishido T; Kikuchi M; Asai J. Primary gastric Ki-1 positive anaplastic large cell lymphoma: a report of two cases. *Pathol Int*, 1994, 44(2):164-9.
6. Tay YK; Tan KC; Wong WK; Ong BH. Papuloerythroderma of Ofuji: a report of three cases and review of the literature. *British Journal of Dermatology*, 1994, 130(6):773-6.
7. Wang HH; Mangano MM; Antonioli DA. Evaluation of T-lymphocytes in esophageal mucosal biopsies. *Modern Pathology*, 1994, 7(1):55-8.
8. Albrecht S; Bruner JM; Segall GK. Immunoglobulin heavy chain rearrangements in primary brain lymphomas. A study using PCR to amplify CDR-III. *J of Pathol*, 1993, 169:297-302.
9. Alecu M; Ghyka G; Ursaciuc C; Ardeleanu C; Halalau F; Coman G. Tumor infiltrate after local treatment with interferon in squamous cell carcinoma. *Romanian Journal of Internal Medicine*, 1993, 31(3):207-12.
10. Arai E; Su WP; Roche PC; Li CY. Cutaneous histiocytic malignancy. Immunohistochemical re-examination of cases previously diagnosed as cutaneous "histiocytic lymphoma" and "malignant histiocytosis". *Journal of Cutaneous Pathology*, 1993, 20(2):115-20.
11. Banner BF; Sonmez-Alpan E; Yousem SA. An immunophenotypic study of the inflammatory cell populations in colon adenomas and carcinomas. *Modern Pathology*, 1993, 6(3):295-301.
12. Ben-Ezra JM; Stroup RM. Phenotype of bile ducts and infiltrating lymphocytes in graft-versus-host disease. *Transplantation*, 1993, 56(1):162-5.
13. Bluth RF; Casey TT; McCurley TL. Differentiation of reactive from neoplastic small-cell lymphoid aggregates in paraffin-embedded marrow particle preparations using L-26 (CD20) and UCHL-1 (CD45RO) monoclonal antibodies. *American Journal of Clinical Pathology*, 1993, 99(2):150-6.
14. Font RL; Laucirica R; Patrinely JR. Immunoblastic B-cell malignant lymphoma involving the orbit and maxillary sinus in a patient with acquired immune deficiency syndrome. *Ophthalmology*, 1993, 100(6):966-70.
15. Furihata M; Ohtsuki Y; Sonobe H; Araki K; Ogata T; Toki T; Ogoshi S; Tamiya T. Prognostic significance of simultaneous infiltration of HLA-DR-positive dendritic cells and tumor infiltrating lymphocytes into human esophageal

carcinoma. *Tohoku Journal of Experimental Medicine*, 1993, 169(3):187-95.

16. Hakimian D; Tallman MS; Kiley C; Peterson L. Detection of minimal residual disease by immunostaining of bone marrow biopsies after 2-chlorodeoxyadenosine for hairy cell leukemia. *Blood*, 1993, 82(6):1798-802.

17. Hayden DW; Waters DJ; Burke BA; Manivel JC. Disseminated malignant histiocytosis in a golden retriever: clinicopathologic, ultrastructural, and immunohistochemical findings. *Veterinary Pathology*, 1993, 30(3):256-64.

18. Helm KF; Lookingbill DP; Marks JG Jr. A clinical and pathologic study of histiocytosis X in adults. *Journal of the American Academy of Dermatology*, 1993, 29:166-70.

19. Heufelder AE; Bahn RS. Elevated expression in situ of selectin and immunoglobulin superfamily type adhesion molecules in retroocular connective tissues from patients with Graves' ophthalmopathy. *Clinical and Experimental Immunology*, 1993, 91(3):381-9.

20. Kanavaros P; Mikol J; Nemeth J; Galian A; Vaunaize J; Morinet F; Thurel C. Primary T-cell malignant lymphoma of the central nervous system. Histological, immunohistochemical and ultrastructural study of a case. *Pathology, Research and Practice*, 1993, 189(1):93-8; discussion 98-101.

21. Kon S; Sato T; Onodera K; Satoh M; Kikuchi K; Imai S; Osato T. Detection of Epstein-Barr virus DNA and EBV-determined nuclear antigen in angioimmunoblastic lymphadenopathy with dysproteinemia type T cell lymphoma. *Pathology, Research and Practice*, 1993, 189(10):1137-44.

22. Kurtin PJ; Roche PC. Immunoperoxidase staining of non-Hodgkin's lymphomas for T-cell lineage associated antigens in paraffin sections. Comparison of the performance characteristics of four commercially available antibody preparations. *American Journal of Surgical Pathology*, 1993, 17(9):898-904.

23. Liu G; Butany J; Wanless IR; Cameron R; Greig P; Levy G. The vascular pathology of human hepatic allografts. *Human Pathology*, 1993, 24(2):182-8.

24. McCarthy JM; White VA; Harris G; Simons KB; Kennerdell J; Rootman J. Idiopathic sclerosing inflammation of the orbit: immunohistologic analysis and comparison with retroperitoneal fibrosis. *Modern Pathology*, 1993, 6(5):581-7.

25. Mshana RN; Boulandi J; Mayombo J; Mendome G. In vitro lymphoproliferative responses to malaria antigens: a prospective study of residents of a holoendemic area with



**CD45RO (T-Cell Marker) Ab-1 (Clone UCHL-1)**

Mouse Monoclonal Antibody

**Cat. #MS-112-P0, -P1, or -P (0.1ml, 0.5ml, or 1.0ml at 100µg/ml)** (Purified Ab with BSA and Azide)**Cat. #MS-112-P1ABX or -PABX (0.1ml or 0.2ml at 1.0mg/ml)** (Purified Ab without BSA and Azide)**Cat. #MS-112-R7 (7.0ml)** (Ready-to-Use for Immunohistochemistry)**Cat. #MS-112-RQ (12.0ml)** (Ready-to-use for Immunohistochemistry)**Cat. #MS-112-PCS (5 Slides)** (Positive Control for Histology)**Please note this data sheet has been changed effective December 6, 2011**

perennial malaria transmission. *Parasite Immunology*, 1993, 15:35-45.

**26.** Takahashi H; Fujita S; Okabe H; Tsuda N; Tezuka F. Immunophenotypic analysis of extranodal non-Hodgkin's lymphomas in the oral cavity. *Pathology, Research and Practice*, 1993, 189:300-11.

**27.** Tallini G; West AB; Buckley PJ. Diagnosis of gastrointestinal T-cell lymphomas in routinely processed tissues. *Journal of Clinical Gastroenterology*, 1993, 17(1):57-66.

**28.** Welch ML; Smith KJ; Skelton HG; Frisman DM; Yeager J; Angritt P; Wagner KF. Immunohistochemical features in inflammatory linear verrucous epidermal nevi suggest a distinctive pattern of clonal dysregulation of growth. *Military Medical Consortium for the Advancement of Retroviral Research. Journal of the American Academy of Dermatology*, 1993, 29(2 Pt 1):242-8.

**29.** Chadburn A; Husain S; Knowles DM. Monoclonal antibody OPD4 detects neoplastic T cells but does not distinguish between CD4 and CD8 neoplastic T cells in paraffin tissue sections. *Human Pathology*, 1992, 23(8):940-7.

**30.** Clayton F; Reka S; Cronin WJ; Torlakovic E; Sigal SH; Kotler DP. Rectal mucosal pathology varies with human immunodeficiency virus antigen content and disease stage. *Gastroenterology*, 1992, 103(3):919-33.

**31.** Iwafuchi M; Watanabe H; Maejima T; Okamura N; Miwa K. Inflammatory pseudotumor of the spleen. Report of a case with an immunohistochemical study. *Acta Pathologica Japonica*, 1992, 42(5):376-81.

**32.** Jakic-Razumovic J; Browne MD; Sale GE. Proliferation rates in epidermis of patients with graft-versus-host disease, non-specific inflammation and normal skin. *Bone Marrow Transplantation*, 1992, 10(1):27-31.

**33.** Lopez-Gil F; Roura M; Umberto I; Umberto P. Malignant proliferative angioendotheliomatosis or angiotropic lymphoma associated with a soft-tissue lymphoma. *Journal of the American Academy of Dermatology*, 1992, 26(1):101-4.

**34.** Mangano MM; Antonioli DA; Schnitt SJ; Wang HH. Nature and significance of cells with irregular nuclear contours in esophageal mucosal biopsies. *Modern Pathology*, 1992, 5(2):191-6.

**35.** Milei J; Storino R; Fernandez Alonso G; Beigelman R; Vanzulli S; Ferrans VJ. Endomyocardial biopsies in chronic chagasic cardiomyopathy. *Immunohistochemical and ultrastructural findings. Cardiology*, 1992, 80:424-37.

**36.** Ohara Y; Iwasaki Y; Izumo S; Kobayashi I; Yoshioka A. Search for human T-cell leukemia virus type I (HTLV-I) proviral sequences by polymerase chain reaction in the central nervous system tissue of HTLV-I-associated myelopathy. *Archives of Virology*, 1992, 124:31-43.

**37.** Ratnam KV; Su WP; Ziesmer SC; Li CY. Value of immunohistochemistry in the diagnosis of leukemia cutis: study of 54 cases using paraffin-section markers. *Journal of Cutaneous Pathology*, 1992, 19(3):193-200.

**38.** Smith KJ; Skelton HG; Yeager J; Angritt P; Wagner K; James WD; Giblin WJ; Lupton GP. Cutaneous histopathologic, immunohistochemical, and clinical manifestations in patients with hemophagocytic syndrome. *Military Medical Consortium for Applied Retroviral Research (MMCARR). Archives of Dermatology*, 1992, 128(2):193-200.

**39.** Sumiyoshi Y; Kikuchi M; Takeshita M; Yoneda S; Kobari S; Ohshima K. Immunohistological study of skin involvement in Kikuchi's disease. *Virchows Archiv. B. Cell Pathology*, 1992, 62(4):263-9.

**40.** Suster S. Large cell lymphoma of the mediastinum with marked tropism for germinal centers. *Cancer*, 1992, 69(12):2910-6.

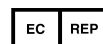
**41.** Travis WD; Fox CH; Devaney KO; Weiss LM; O'Leary TJ; Ognibene FP; Suffredini AF; Rosen MJ; Cohen MB; Shelhamer J. Lymphoid pneumonitis in 50 adult patients infected with the human immunodeficiency virus: lymphocytic interstitial pneumonitis versus nonspecific interstitial pneumonitis. *Human Pathology*, 1992, 23:529-41.

**42.** van der Wal AC; Becker AE; Elbers JR; Das PK. An immunocytochemical analysis of rapidly progressive atherosclerosis in human vein grafts. *European Journal of Cardio-Thoracic Surgery*, 1992, 6(9):469-73; discussion 474.

**43.** Werner M; Kaloutsi V; Walter K; Buhr T; Bernhards J; Georgii A. Immunohistochemical examination of routinely processed bone marrow biopsies. *Pathology, Research and Practice*, 1992, 188(6):707-13.

**44.** Aozasa K; Ohsawa M; Saeki K; Horiuchi K; Tamai M; Kohro T; Kurata A. Histiocytic neoplasias: immunohistochemical evaluation of their frequencies among malignant lymphoma and related conditions in Japan. *Journal of Surgical Oncology*, 1991, 47(4):215-20.

**45.** Arbustini E; Grasso M; Diegoli M; Bramerio M; Foglieni AS; Albertario M; Martinelli L; Gavazzi A; Goggi C; Campana C; et al. Expression of tumor necrosis factor in human acute cardiac rejection. An immunohistochemical



**CD45RO (T-Cell Marker) Ab-1 (Clone UCHL-1)**

Mouse Monoclonal Antibody

**Cat. #MS-112-P0, -P1, or -P (0.1ml, 0.5ml, or 1.0ml at 100µg/ml)** (Purified Ab with BSA and Azide)**Cat. #MS-112-P1ABX or -PABX (0.1ml or 0.2ml at 1.0mg/ml)** (Purified Ab without BSA and Azide)**Cat. #MS-112-R7 (7.0ml)** (Ready-to-Use for Immunohistochemistry)**Cat. #MS-112-RQ (12.0ml)** (Ready-to-use for Immunohistochemistry)**Cat. #MS-112-PCS (5 Slides)** (Positive Control for Histology)**Please note this data sheet has been changed effective December 6, 2011**

and immunoblotting study. *American Journal of Pathology*, 1991, 139:709-15.

**46.** Berti E; Aversa GG; Soligo D; Cattoretti G; Delia D; Aiello A; Parravicini C; Hall BM; Caputo R. A6--a new 45RO monoclonal antibody for immunostaining of paraffin-embedded tissues. *American Journal of Clinical Pathology*, 1991, 95(2):188-93.

**47.** Broide DH; Firestein GS. Endobronchial allergen challenge in asthma. Demonstration of cellular source of granulocyte macrophage colony-stimulating factor by in situ hybridization. *Journal of Clinical Investigation*, 1991, 88(3):1048-53.

**48.** Caldwell CW; Marty LM; Feldbush TL. Expression of the low Mr isoform of CD45 (CD45RO) in B-cell non-Hodgkin's lymphomas. *Clinical Immunology and Immunopathology*, 1991, 58(3):377-84.

**49.** Campo E; Cardesa A; Alos L; Palacin A; Cobarro J; Traserra J; Montserrat E. Non-Hodgkin's lymphomas of nasal cavity and paranasal sinuses. An immunohistochemical study. *American Journal of Clinical Pathology*, 1991, 96(2):184-90.

**50.** Cillari E; Milano S; Dieli M; Maltese E; Di Rosa S; Mansueto S; Salerno A; Liew FY. Reduction in the number of UCHL-1+ cells and IL-2 production in the peripheral blood of patients with visceral leishmaniasis. *Journal of Immunology*, 1991, 146(3):1026-30.

**51.** Della Croce DR; Imam A; Brynes RK; Nathwani BN; Taylor CR. Anti-BLA.36 monoclonal antibody shows reactivity with Hodgkin's cells and B lymphocytes in frozen and paraffin-embedded tissues. *Hematological Oncology*, 1991, 9:103-14.

**52.** DePalma L; Duncan B; Chan MM; Luban NL. The neonatal immune response to washed and irradiated red cells: lack of evidence of lymphocyte activation. *Transfusion*, 1991, 31(8):737-42.

**53.** Gonzalez CL; Medeiros LJ; Jaffe ES. Composite lymphoma. A clinicopathologic analysis of nine patients with Hodgkin's disease and B-cell non-Hodgkin's lymphoma. *American Journal of Clinical Pathology*, 1991, 96(1):81-9.

**54.** Hasui K. Paraffin-immunohistochemical analysis of 226 non-Hodgkin's malignant lymphomas in the endemic area of human T-cell leukemia virus type 1. *Acta Pathologica Japonica*, 1991, 41(5):350-62.

**55.** LaSalle JM; Hafler DA. The coexpression of CD45RA and CD45RO isoforms on T cells during the S/G2/M stages of cell cycle. *Cellular Immunology*, 1991, 138(1):197-206.

**56.** Min KW; Holmquist S; Peiper SC; O'Leary TJ. Poorly differentiated adenocarcinoma with lymphoid stroma (lymphoepithelioma-like carcinomas) of the stomach. Report of three cases with Epstein-Barr virus genome demonstrated by the polymerase chain reaction. *American Journal of Clinical Pathology*, 1991, 96(2):219-27.

**57.** Ohshima K; Kikuchi M; Yoshida T; Masuda Y; Kimura N. Lymph nodes in incipient adult T-cell leukemia-lymphoma with Hodgkin's disease-like histologic features. *Cancer*, 1991, 67(6):1622-8.

**58.** Pelstring RJ; Allred DC; Esther RJ; Lampkin SR; Banks PM. Differential antigen preservation during tissue autolysis. *Human Pathology*, 1991, 22(3):237-41.

**59.** Regezi JA; Zarbo RJ; Stewart JC. Extranodal oral lymphomas: histologic subtypes and immunophenotypes (in routinely processed tissue). *Oral Surgery, Oral Medicine, Oral Pathology*, 1991, 72(6):702-8.

**60.** Shumack S; Commens C; Kossard S. Disseminated superficial actinic porokeratosis. A histological review of 61 cases with particular reference to lymphocytic inflammation. *American Journal of Dermatopathology*, 1991, 13(1):26-31.

**61.** Skopouli FN; Fox PC; Galanopoulou V; Atkinson JC; Jaffe ES; Moutsopoulos HM. T cell subpopulations in the labial minor salivary gland histopathologic lesion of Sjogren's syndrome. *Journal of Rheumatology*, 1991, 18(2):210-4.

**62.** Takeshita M; Muller H; Mix D; Stutte HJ; Schmidts HL. Immuno- and enzyme histochemical characterization of 'plasmacytoid T-cells' in formalin-fixed paraffin-embedded tissue of reactive lymph nodes. *Pathology, Research and Practice*, 1991, 187(7):848-55.

**63.** Tateyama H; Eimoto T; Tada T; Kamiya M; Fujiyoshi Y; Kajura S. Genital angiotropic lymphoma (intravascular lymphomatosis) of the T-cell type. *Cancer*, 1991, 67(8):2131-6.

**64.** Taubenberger JK; Cole DE; Raffeld M; Poplack DG; Jaffe ES; Medeiros LJ. Immunophenotypic analysis of acute lymphoblastic leukemia using routinely processed bone marrow specimens. *Archives of Pathology and Laboratory Medicine*, 1991, 115:338-42.

**65.** Toyota N; Matsuo S; Iizuka H. Immunohistochemical differential diagnosis between lymphocytoma cutis and malignant lymphoma in paraffin-embedded sections. *Journal of Dermatology*, 1991, 18(10):586-91.

**66.** Zukerberg LR; Harris NL; Young RH. Carcinomas of the urinary bladder simulating malignant lymphoma. A



---

**CD45RO (T-Cell Marker) Ab-1 (Clone UCHL-1)**

Mouse Monoclonal Antibody

**Cat. #MS-112-P0, -P1, or -P (0.1ml, 0.5ml, or 1.0ml at 100µg/ml)** (Purified Ab with BSA and Azide)

**Cat. #MS-112-P1ABX or -PABX (0.1ml or 0.2ml at 1.0mg/ml)** (Purified Ab without BSA and Azide)

**Cat. #MS-112-R7 (7.0ml)** (Ready-to-Use for Immunohistochemistry)

**Cat. #MS-112-RQ (12.0ml)** (Ready-to-use for Immunohistochemistry)

**Cat. #MS-112-PCS (5 Slides)** (Positive Control for Histology)

Please note this data sheet has been changed effective December 6, 2011

report of five cases. American Journal of Surgical Pathology, 1991, 15(6):569-76.

67. Alpers CE; Gordon D; Gown AM. Immunophenotype of vascular rejection in renal transplants. Modern Pathology, 1990, 3(2):198-203.

